

UNDERSTANDING BREAST DENSITY

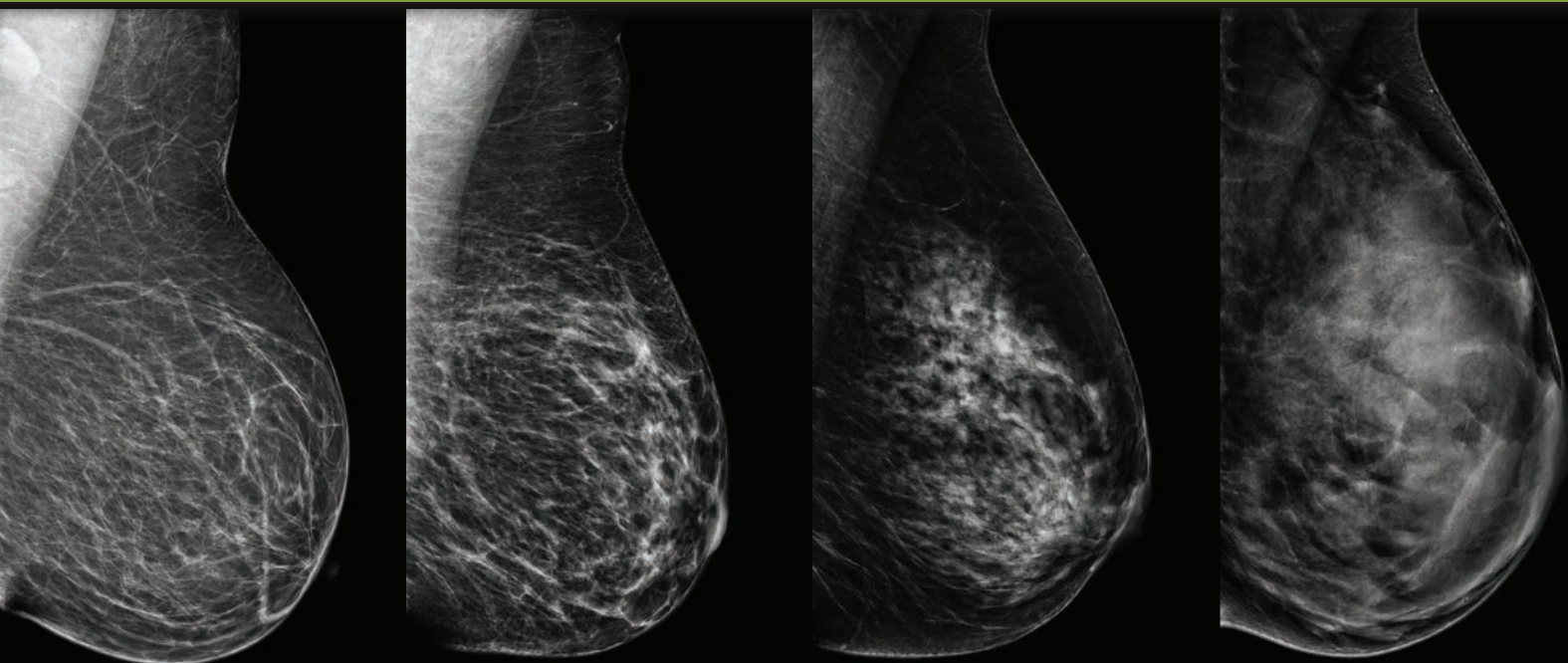
All breasts are not the same.

I've been told that I have dense breast tissue – what does that mean?

Breasts are made of fat and breast tissue. When there is more breast tissue than fat, breasts are considered to be dense. On a mammogram, dense tissue looks white. Since masses or lumps also appear white on a mammogram, a lump may be hidden by the dense breast tissue. Dense breast tissue is also linked with an increase in the risk of developing breast cancer.

Having dense breast tissue normal; it is a part of you, like having green eyes or brown hair. Dense breast tissue is common; 40% of women have dense breast tissue. Since mammography has limited visibility in women with dense breast tissue, screening dense breasts with ultrasound, in addition to mammography, may improve the likelihood of detecting cancer.

All women should discuss personal risk factors, including breast density, with their physician.



Almost entirely fatty

Scattered fibroglandular densities

Heterogeneously dense

Extremely dense



GUNNISON VALLEY HEALTH

WWW.GUNNISONVALLEYHEALTH.ORG/ABUS

What you need to know about breast density.

It's in the media, your mammography report mentions it and now some states even have a law about it.

Breast tissue consists of fatty and fibroglandular tissue. Dense breast tissue is defined as having a higher percentage of fibroglandular tissue within your breasts. If more than 50% of your breast is made of fibroglandular tissue, then your breasts are classified as "dense." The sensitivity of mammography is significantly diminished in women with dense breast tissue.¹ Additionally, women with dense breast tissue have a 4-6 times higher risk of developing breast cancer than women with minimal fibroglandular tissue in their breasts.²

Looking for a snowball in a snowstorm?

You may have heard the statement that looking for cancer in dense breast tissue is like looking for a snowball in a snowstorm. This is a descriptive way of explaining why dense breast tissue can potentially mask breast cancers. On an X-ray mammogram, both dense breast tissue and cancers show up as white. Therefore, with mammography, a cancer can easily hide in a background of dense breast tissue since they both appear white. Alternatively, in fatty tissue, which is gray, a white mass (cancer) can be readily identified.

My breasts don't feel dense so I must not have dense breast tissue, right?

Breast density cannot be determined by palpation or by the appearance of the breasts – it can only be determined by evaluating a mammogram. Your radiologist performs your breast density assessment at the time your mammogram is reviewed.

Isn't dense breast tissue only a problem for young women?

Generally speaking, it is true that younger women usually have denser breast tissue and most women will have fatty replacement of dense glandular breast tissue as they age. However, that being said, 74% of women in their 40s, 57% of women in their 50s, 44% of women in their 60s and 36% of women in their 70s have dense breast tissue.³

Does this mean that something is wrong with me?

No, having dense breast tissue is not an abnormal condition. It is a feature of your body. Over 40% of women in the United States have dense breast tissue.⁴

How can I stop having dense breast tissue?

Dense breast tissue is a physical attribute like other features of your body. It is not something that you can actively try to change or improve. The best thing to do is to become informed, know your personal risk factors and participate in regular breast screening.

What about 3D mammography? I've heard that it is better for dense breast tissue.

3D mammography has been found to be more effective for women with dense breasts tissue. However, even 3D mammography has limitations in dense breast tissue.⁴

Does this mean that I no longer need a mammogram?

Mammography is still the gold standard. Supplemental imaging is meant to complement mammography, not replace it. If your doctor recommends a breast ultrasound exam, it should not be performed in isolation.

1. Mandelson et al. Breast density as a predictor of mammographic detection: comparison of interval- and screen-detected cancers. *J Natl Cancer Inst* 2000; 92: 1081-1087.

2. Boyd NF et al. Mammographic Density and the Risk and Detection of Breast Cancer. *NEJM* 2007; 356: 227-36.

3. Checka CM, Chun JE, Schnabel FR, Lee J, Toth H. The relationship of mammographic density and age: implications for breast cancer screening. *AJR Am J Roentgenol*. 2012 Mar; 198 (3): W292-5.

4. Tagliafico, Massimo Calabrese et al, *Journal of Clinical Oncology* 2016 34:16, 1882-1888.

**For more information contact the Gunnison Valley Health
Radiology Department at 970-641-7253.**



GUNNISON VALLEY HEALTH

WWW.GUNNISONVALLEYHEALTH.ORG/ABUS